

A.M. Issimov, N.K. Kemalova*, A.T. Sarzhigitova, B. Bakytzhankyzy

Aktobe regional university named after K. Zhubanova, Aktobe, Kazakhstan

**Corresponding author: Knk17@bk.ru*

The first lumpy skin disease outbreak in cattle in Kazakhstan

Lumpy skin disease (LSD) is an emerging trans-boundary viral disease of cattle originating from the African continent. Here, we describe the first LSD outbreak reported in the Republic of Kazakhstan in July 2016, as well as associated clinical manifestations of the disease, diagnostic methods, and control measures taken to combat further spread of the pathogen. To determine the cause of the disease, samples were taken from sick and dead animals, as well as from insects and ticks. LSDV DNA was detected by PCR in all samples from dead animals and ticks (*Dermacentor marginatus* and *Hyalomma asiaticum*), in 14.29% of samples from horseflies (*Tabanus bromius*), and in one of the samples from two *Stomoxys calcitrans* flies. The reproductive LSD virus was isolated from organs of dead cattle and insects in the culture of LT and MDBK cells. The virus accumulated in cell cultures of LT and MDBK at the level of the third passage with titers in the range of 5.5–5.75 log₁₀ TCID₅₀/cm³. During the outbreak, the number of affected cattle within an epidemiological unit reached 459 cattle out of 3557 registered susceptible cattle, with 12.90% morbidity and 0.96% mortality. This manuscript presents the epidemiological situation; the diagnosis; the control measures, including mass vaccination; and the stamping out campaign.

Keywords: control measures, diagnosis, epidemiological data, lumpy skin disease, *Stomoxys calcitrans*, *Hematobia irritans*, outbreak.

Introduction

Lumpy skin disease virus (LSDV) belongs to the *Capripoxvirus* genus of the, *Poxviridae* family, is a highly contagious infectious disease of cattle. It is characterized by fever, skin nodules, enlargement of superficial lymph nodes, salivation, lacrimation and nasal discharge as well as oedema and swellings of the joints and the dewlap [1]. The World Organization for Animal Health classifies Lumpy Skin Disease (LSD) as a noticeable disease due to its significant economic impact [2].

LSDV was first discovered in Zambia, where it was recorded in 1929. Subsequently, LSDV has become endemic almost the whole African continent and in the Middle East, Turkey, Azerbaijan continuing to spread to the North posing a threat to Europe and the Central Asian region. In 2015, LSD outbreaks were documented in Greece [3], from where it spread to the Balkan region. Similarly, in 2015, the disease was clinically confirmed in North Caucasus of Russia where it becomes epidemic and spread throughout the country [4, 5]. In 2016, LSD re-emerged in several regions of Southern Russia, including Astrakhan oblast bordering with Atyrau region in West Kazakhstan.

The paper aims to report on the first occurrence of LSD in the Republic of Kazakhstan and to describe the associated clinical features of the disease, diagnostic methods as well, as control measures taken to eliminate further dissemination of the pathogen.

According to Statistic Bureau of Agro-industrial complex of Ministry of Agriculture of the Republic of Kazakhstan the total cattle population of the country is estimated to be about 7.161 million heads, mostly local breeds (87.1%); the remaining are hybrids and exotic breeds (data not available). The livestock system practiced in the country is mixed farming, including intensive, small-scale beef and dairy management. Live animals are not exported from the country; meanwhile, the export share of animal products in 2017 accounted for 20 thousand tons. In rural areas, cattle are the primary source of income and mainly kept for milk and meat production. The commercial smallholding dairy and beef farms are mostly market-oriented and located around urban areas practicing intensive management.

Experimental

Animal Ethics

The protocol was approved by the Committee on the Ethics of Animal Experiments of the Research Institute for Biological Safety Problems (RIBSP) of the Science Committee of Ministry of Education and Science of the Republic of Kazakhstan (permit number: 1205/106).

Place on investigation are noted in Figure 1.

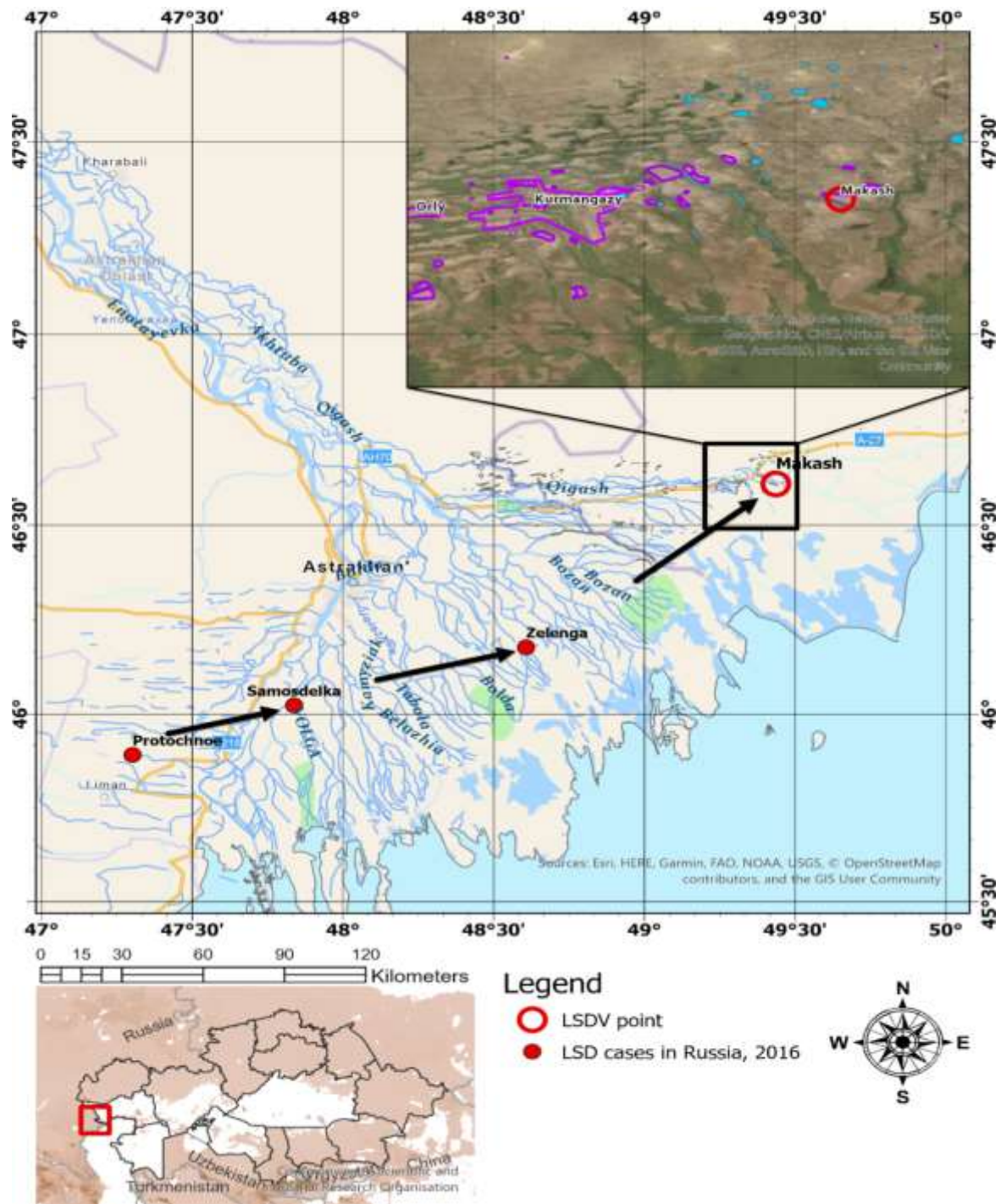


Figure 1. The location of the LSD outbreak in Atyrau region. Areas drawn in pink – indicate seasonal communal grazing lands (Food and Agriculture Organization (FAO))

Blood samples and skin lesions (Fig. 2) were collected for testing to the Virology section of the BSL-3 laboratory of the RIBSP and to OIE Reference Laboratory, All-Russian Research Institute for Animal Health (ARRIAH).



Figure 2. Cattle exhibiting LSD characteristic clinical signs in the outbreak foci in Republic of Kazakhstan in 2016. The body surface of infected animals exhibited extensive circumscribed and convex skin nodules (a-d) with ulceration of the scrotum and the teats (e-f)

Control Measures

In the first affected farm, a total stamping out as well as incineration of carcasses were undertaken to prevent the spread of the disease locally. Quarantine and cattle movement controls were initiated within the Kurmangazy District, as well as strict restrictions on vehicles commuting to and from the affected zones. In addition, ring vaccination were conducted in a radius of 30 km. Such a significant coverage explained by the high density of livestock population and use of common grazing lands on South and West from the initial foci. In Kazakhstan, vaccination campaign was launched immediately after notification was sent to OIE, more than 70.000 cattle in the affected areas and neighboring regions (Makhambet, Isatay, Makat) were vaccinated during the vaccination campaign. A total of one million doses of LSD vaccine (LUMPIVAX®,

Neethling-type, Kenya) were purchased before the outbreak and used in cattle against LSD. In Makash, veterinary personnel that were involved in LSD control and eradication campaign wore personal protective equipment (PPE) when visiting affected farms. Moreover, animal premises (walls, ceilings and floor) were disinfected, utilizing Lysoformin 3000. Farmers were instructed to apply the disinfectants every day.

In response to the LSD outbreak in 2016 on the Russian side of the border, the veterinary authorities culled only those cattle showing typical clinical signs (partial stamping out) and implemented movement restrictions. Susceptible cattle were treated with insect repellents and vaccinated with a heterologous live sheeppox virus vaccine at a dose of 10⁻⁴ TCID₅₀, produced locally by ARRIAH [5-7]. An eradication program was enacted according to the State Contingency Plan (Directive N 339-2) after field samples provided positive results using conventional PCR.

Until 21 July 2016, in the Kurmangazy District, among the officially registered 3557 cattle, the number of affected cattle reached 459 with morbidity and mortality rates accounting for 12.90% and 0.96% respectively. The case fatality rate was 7.41% [8, 9]. Kazakhstan veterinary services carried out a total stamping out measure at this first affected farm.

Sample collection

Samples were taken from 96 cattle of different ages and sexes with clinical signs characteristic of FMD. In severe cases, there was an increase in body temperature up to 42°C followed by severe salivation, nasal discharge and inflammation of the mucous membranes. The body surfaces of infected animals were completely covered with circumscribed and convex nodules, which were hard and rough when palpated. Animals exhibiting mild symptoms of FMD showed enlargement of superficial lymph nodes and edema of the limbs and brisket. A total of 74 blood samples, 47 skin lesions, 4 samples of internal organs (2 lymph nodes, 2 lung tissue samples), were taken from diseased and dead animals by official field veterinarians and dispatched to the RIBSP. In addition, 14 hard ticks attached to the diseased host were collected during the clinical examination of infected animals. Moreover, 21 horn flies (*Hematobia irritans*) and 25 stable flies (*Stomoxys calcitrans*) were caught within livestock premises using a commercial fly catching unit “Miniature CDC light trap with UV light” (USA) to investigate a possible insect vector involvement in the transmission of LSD in the field. The light trap was hung from the ceiling of the barn and checked every two hours for insects. The time of insect collection was determined as follows: 12 hours during the night.

Virus isolation

Virus isolation (VI) was conducted according to Standard Operational Procedures of the BSL-3 laboratory of the RIBSP. The tests were carried out as described by OIE (2018). Briefly, 1 ml buffy coat or supernatant were administered on to lamb testes cells in 25 cm² cell culture flasks and allowed to incubate at 37°C for 1 hour. Following incubation cell culture growth media was removed and cell monolayer was rinsed with PBS and overlaid with Glasgow's Minimal Essential Medium containing 0.1% penicillin, 0.2% gentamycin and 2% fetal calf serum (Thermo Fisher Scientific). The cell monolayer was examined daily for characteristic cytopathic effect (CPE). In the case no CPE was observed, the cell culture was freeze-thawed three times and second or third blind passages were carried out. Cell culture flasks showing CPE were tested with gel-based PCR to confirm that the CPE change was induced by LSDV.

Virus detection by PCR

A PCR assay was performed using the protocol published by Tuppurainen, Venter, and Coetzer [10, 11]. For DNA extraction, a QIAamp DNA Kit (QIAGEN, USA) was used according to manufacturer's instructions.

For PCR assay, to produce 192 bp of amplified nucleotides reactions the forward 5'-TCC-GAG-CTC-TTT-CCT-GAT-TTT-TCT-TAC-TAT-3' and reverse 5'-TAT-GGT-ACC-TAA-ATT-ATA-TAC-GTA-AAT-AAC-3' primers were used [12]. The conditions for DNA amplification in a Thermal Cycler (Eppendorf Mastercycler) were as follows: 95°C for 2 min, 95°C for 45 s, 50°C for 50 s, 72°C for 1 min (34 cycles) and 72°C for 2 min. Obtained PCR products were loaded in 1.5% agarose-gel electrophoresis and the results visualized using Bio-imaging systems MiniBIS Pro (Israel).

Complete genome sequencing of LSDV field strain was performed in collaboration with Kazakh Scientific-Research Veterinary Institute LLP (Kazakhstan) and Sciensano, Unit Exotic Viruses and Particular Diseases (Belgium) and has been deposited in GenBank under accession number MN642592 (LSDV isolate Kubash/KAZ/16) [13].

Results

PCR and Virus isolation

From 7th July until the end of November 2016, three outbreaks were confirmed within Makash village. A total number of 425 cattle were disposed of in the eradication program. A total of 185 samples were tested by PCR and VI. The presence of viral nucleic acid was laboratory-confirmed in a total of 102 samples, whereas 52 samples tested positive for VI. All skin lesions tested positive by PCR and VI. Viral DNA was detected in 24 of 74 blood samples and whereas virus isolation revealed a LSDV characteristic CPE in 3 out of 74 blood samples. Internal organs were tested positive by PCR, while it was not possible to isolate a live virus in cell culture infected from lymph nodes or lungs (Table). In addition, LSDV DNA was recovered from 6 out of 14 ticks, 8 out of 21 horn flies and 14 out of 25 stable flies' samples while live virus was isolated only from 2 out of 25 *Stomoxys calcitrans* samples.

Table

Summary of PCR and Virus isolation testing results [14]

Type of Sample	PCR (Positive result)	Virus isolation (Positive result)	Mean Ct value
Skin lesions	47/47	47/47	16.7
Blood	24/74	3/74	27.1
Lung	1/2	0/2	11.3
Lymph nodes	2/2	0/2	15.8
Dermacentor	6/14	0/14	16.4
<i>Stomoxys calcitrans</i>	14/25	2/25	24.3
<i>Hematobia irritans</i>	8/21	0/21	22.9

Discussion

Epidemiological investigation

To date, the source of infection and the mode of transmission of the virus to Kazakhstan remain unclear. This issue is especially urgent for trans-boundary infections. Most researchers believe that spread of the causative agent of LSD outside the epizootic focus region to a new area happens due to unauthorized movements of infected animals in the presence of insect vector [15]. These assumptions could be supported by the presence of river delta along border, which is thought to be auspicious habitat for reproduction of the insect vectors. Transmission of LSDV within the herd occurs by aerosols when a sick animal exhales, via direct contact between animals, through contaminated water and feed or by blood-feeding insect [16, 17]. It has been suggested that the spread of LSD into countries such as Iran, Azerbaijan, Republic of Dagestan, Georgia and Russia Federation was associated with the direct and indirect animal contacts when the farmers were using shared pasture lands between the bordering states [18]. Thus, practicing communal grazing and illegal animal trading between trans-boundary farms can serve as source of LSDV introduction into new area. Azerbaijan scientist suggested that also the role of human factors could be involved in mechanical transmission of the pathogen via direct contact with infected animals and their environment, farm workers may transport and spread virus to healthy herd [4]. In addition, Annandale et al. [19] reported that cattle insemination with infectious semen lead to disease development.

Despite assumption in the transmission of LSD mentioned above, it is generally accepted that a variety of blood-feeding insects play a significant role in LSDV transmission by acting as mechanical vectors. According to the epizootic investigation outcomes of LSD outbreaks in Egypt, it was considered highly likely that the pathogen was transferred by stable flies (*Stomoxys calcitrans*) [20]. This assumption was based on the seasonality of outbreaks of LSD, occurring during hot and wet summer seasons [6, 16, 21]. In recent studies, LSDV transmission from diseased to susceptible cattle by *Stomoxys* species have been demonstrated successfully under laboratory condition [15, 22].

A mathematical model of synoptic system used in recent study to calculate air long-distance dispersal (LDD) of LSDV in Israel revealed that LDD transmission by air is a feasible way of dissemination of vector borne diseases in the Middle East and should be taken into consideration when evaluating risk for new outbreaks [23]. In other studies, mathematical modeling revealed that under natural conditions the blood-feeding insects range rarely exceeds 5 km [24]. Moreover, wind has a direct impact on insect distribution [25]. Such a significant coverage range and vector capability of stable flies to carry pathogen may lead to

LSDV escape from the initial outbreak foci and rapid dissemination over neighboring farms. In relatively recent clinical experiments, the potential of ticks as a mechanical vector has been successfully demonstrated. Ticks in different molting stages have carried LSDV following feeding to repletion on artificially infected animals [26, 27]. In addition, LSDV has been detected in the saliva of mature ticks making them capable of virus transmission.

In the Kazakhstani scenario of disease development, LSD was recorded mostly among emaciated animals, lactating cows, and calves. During the current LSD epidemic in Kazakhstan, the morbidity and mortality rates constituted 12.90% and 0.96% respectively. Due to rapid response of State Veterinary Service in combination of strict quarantine, stamping out and mass vaccination campaign allowed limiting LSD outbreak within the initial foci.

In our study, several arthropod species including ixodid ticks (*Dermacentor marginatus* and *Hyalomma asiaticum*), horseflies (*Tabanus bromius*), and other biting flies (*Stomoxys calcitrans*) collected in the disease focus were assayed as potential transmitters. All tick samples were positive, and a proportion of horse flies and *Stomoxys* flies. The first LSDV isolate in cell culture was obtained from sampled horseflies (*Tabanus bromius*) collected during the outbreak of the disease. These results support the studies of Sohier et al. (2019), which showed experimentally that horseflies can mechanically transmit LSDV. We have shown that all individuals sampled, of both species of ticks collected from the region of the outbreak of the disease, were PCR positive for LSDV, and the virus was isolated from the pool of ticks of both species, through cell culture. Until 21 July 2016, in the Kurmangazy District, among the officially registered 3557 cattle, the number of affected cattle reached 459 with morbidity and mortality rates accounting for 12.90% and 0.96% respectively. The case fatality rate was 7.41% (OIE 2016). Kazakhstan veterinary services carried out a total stamping out measure at this first affected farm.

Conclusion

Given the fact that there is a significant density of livestock in the West Kazakhstan oblast and unauthorized trade in animals occurs, it is likely that LSD will continue to spread, leading to serious social and economic consequences for the whole country and posing a real threat to animal husbandry of developing countries of the Central Asia.

Studies have shown that a new disease in cattle in the Atyrau region of Kazakhstan in 2015 was caused by FMD infection. The virus was also detected among *Tabanus bromius* and *Stomoxys calcitrans*, indicating the possibility of these species as vectors of FMD in this region.

Acknowledgements

The author is sincerely thankful to Mr Aslan Kerembaev and Ms Raihan Nissanova for technical assistance provided as well as research project.

References

- 1 Davies, F. G. (1991). Lumpy skin disease, an African capripox virus disease of cattle. *British Veterinary Journal*, 147(6); 489-503.
- 2 Tuppurainen, E. S. M. & Oura, C. A. L. (2012). Lumpy skin disease: an emerging threat to Europe, the Middle East and Asia. *Transboundary and emerging diseases*, 59(1); 40-48. <https://doi.org/10.1111/j.1865-1682.2011.01242x>
- 3 Tasioudi, K. E., Antoniou, S. E., Iliadou, P., Sachpatzidis, A., Plevraki, E., Agianniotaki, E. I. & Dile, C. (2016). Emergence of lumpy skin disease in Greece, 2015. *Transboundary and Emerging Diseases*, 63(3), 260-265. <https://doi.org/10.1111/tbed.12497>
- 4 Zeynalova, S., Asadov, K., Guliyev, F., Vatani, M. & Aliyev, V. (2016). Epizootology and molecular diagnosis of lumpy skin disease among livestock in Azerbaijan. *Frontiers in Microbiology*, 1022. <https://doi.org/fmicb.2016.01022>
- 5 Sprygin, A., Artyuchova, E., Babin, Y., Prutnikov, P., Kostrova, E., Byadovskaya, O. & Kononov, A. (2018). Epidemiological characterization of lumpy skin disease outbreaks in Russia in 2016. *Transboundary and emerging diseases*, 65(6); 1514-1521. <https://doi.org/10.1111/tbed.12889>
- 6 Weiss, K. E. (1968). Lumpy skin disease. *Infect. Dis. Livest*, 2; 1268-1278.
- 7 Rouby, S., & Aboulsoud, E. (2016). Evidence of intrauterine transmission of lumpy skin disease virus. *The Veterinary Journal*, 209, 193-195. <https://doi.org/1.1016/j.tvjl.11.010>
- 8 Usadov, T. R., Morgunov, Y. P., Zhivoderov, S. P., Balysheva, V. I., Pivova, E. Y., Koltsov, A. Y., & Salnikov, N. I. (2018). Lumpy skin disease virus, isolated in 2015 in Russia from cattle, is pathogenic for sheep at experimental infection. *Selskokhozyaistvennaya Biologiya*, 53(2); 438-446. <https://doi.org/10.15389/agrobiol.2018.2.438>

- 9 Tuppurainen, E., & Galon, N. (2016). Technical item II lumpy skin disease: Current situation in Europe and neighbouring regions and necessary control measures to halt the spread in south-east Europe. *OIE Regional Commission*.
- 10 World Organization for Animal Health (OIE). (2019). *Manual of Diagnostic Tests and Vaccines for Terrestrial Animals, Chapter 3.4. 12: Lumpy Skin Disease*.
- 11 Tuppurainen, E. S., Venter, E. H., & Coetzer, J. A. W. (2005). The detection of lumpy skin disease virus in samples of experimentally infected cattle using different diagnostic techniques. *Onderstepoort Journal of Veterinary Research*, 72(2); 153-164. <https://doi.org/10.4102/ojvr72i2.213>
- 12 Ireland, D. C., & Binopal, Y. S. (1998). Improved detection of capripoxvirus in biopsy samples by PCR. *Journal of virological methods*, 74(1); 1-7. [https://doi.org/10.1016/s0166-0934\(98\)00035-4](https://doi.org/10.1016/s0166-0934(98)00035-4)
- 13 Mathijs, E., Vandenbussche, F., Saduakassova, M., Kabduldinov, T., Haegeman, A., Aerts, L., & De Clercq, K. (2020). Complete coding sequence of a lumpy skin disease virus strain isolated during the 2016 outbreak in Kazakhstan. *Microbiology Resource Announcements*, 9(4), e01399-19. <https://doi.org/10.1128/MRA.01399-19>
- 14 Issimov, A., Kutumbetov, L., Orynbayev, M. B., Khairullin, B., Myrzakhmetova, B., Sultankulova, K., & White, P. J. (2020). Mechanical Transmission of Lumpy Skin Disease Virus by Stomoxys spp. (*Stomoxys calcitrans*, *Stomoxys sitchensis*, *Stomoxys indica*), Diptera: Muscidae. *Animals*, 10(3); 477. <https://doi.org/10.3390/ani10030477>
- 15 Carn, V. M., & Kitching, R. P. (1995). An investigation of possible routes of transmission of lumpy skin disease virus (Neethling). *Epidemiology & Infection*, 114(1); 219-226. <https://doi.org/10.1017/s0950268800052067>
- 16 Kitching, R. P., & Taylor, W. P. (1985). Transmission of capripoxvirus. *Research in veterinary science*, 39(2); 196-199.
- 17 Mishchenko, A. V. (2015). Bovine lumpy skin disease. *Preventive veterinary medicine*, 491(2).
- 18 Annandale, C. H., Holm, D. E., Ebersohn, K., & Venter, E. H. (2014). Seminal transmission of lumpy skin disease virus in heifers. *Transboundary and emerging diseases*, 61(5); 443-448. <https://doi.org/10.1111/tbed.12045>
- 19 Salib, F. A., & Osman, A. H. (2011). Incidence of lumpy skin disease among Egyptian cattle in Giza Governorate, Egypt. *Veterinary world*, 4(4). <https://doi.org/10.5455/vetworld.2011.162-167>
- 20 Magori-Cohen, R., Louzoun, Y., Herziger, Y., Oron, E., Arazi, A., Tuppurainen, E., & Klement, E. (2012). Mathematical modelling and evaluation of the different routes of transmission of lumpy skin disease virus. *Veterinary research*, 43(1); 1-13. <https://doi.org/10.1186/1297-9716-43-1>
- 21 Sohler, C., Haegeman, A., Mostin, L., De Leeuw, I., Campe, W. V., De Vleeschauwer, A., & De Clercq, K. (2019). Experimental evidence of mechanical lumpy skin disease virus transmission by *Stomoxys calcitrans* biting flies and *Haematopota* spp. horseflies. *Scientific reports*; 9(1), 1-10. <https://doi.org/10.1038/s41598-019-56605-6>
- 22 Klausner, Z., Fattal, E., & Klement, E. (2017). Using synoptic systems' typical wind trajectories for the analysis of potential atmospheric long-distance dispersal of lumpy skin disease virus. *Transboundary and Emerging Diseases*, 64(2); 398-410. <https://doi.org/10.1111/tbed.12378>
- 23 Gubbins, S., Stegeman, A., Klement, E., Pite, L., Broglia, A., & Abrahantes, J. C. (2020). Inferences about the transmission of lumpy skin disease virus between herds from outbreaks in Albania in 2016. *Preventive veterinary medicine*, 181; 104602. <https://doi.org/10.1016/j.prevetmed.2018.12.008>
- 24 Yeruham, I., Nir, O., Braverman, Y., Davidson, M., Grinstein, H., Haymovitch, M., & Zamir, O. (1995). Spread of lumpy skin disease in Israeli dairy herds. *Veterinary Record*, 137; 91-91. <https://doi.org/10.1136/vr.137.4.91>
- 25 Tuppurainen, E. S., Stoltz, W. H., Troskie, M., Wallace, D. B., Oura, C. A. L., Mellor, P. S., & Venter, E. H. (2011). A potential role for ixodid (hard) tick vectors in the transmission of lumpy skin disease virus in cattle. *Transboundary and emerging diseases*, 58(2); 93-104. <https://doi.org/10.1111/j.1865-1682.2010.01184.x>
- 26 Tuppurainen, E. S., Lubinga, J. C., Stoltz, W. H., Troskie, M., Carpenter, S. T., Coetzer, J. A., & Oura, C. A. (2013). Evidence of vertical transmission of lumpy skin disease virus in *Rhipicephalus decoloratus* ticks. *Ticks and tick-borne diseases*, 4(4), 329-333. <https://doi.org/10.1016/j.ttbdis.2013.01.006>
- 27 Lubinga, J. C., Tuppurainen, E. S. M., Stoltz, W. H., Ebersohn, K., Coetzer, J. A. W., & Venter, E. H. (2013). Detection of lumpy skin disease virus in saliva of ticks fed on lumpy skin disease virus-infected cattle. *Exp Appl Acaro.*, 61(1); 129-138. <https://doi.org/10.1007/s10493-013-9679-5>

А.М. Исимов, Н.К. Кемалова, А.Т. Саржігітова, Б. Бахытжанқызы

Қазақстанда ірі қара малдың сүйелді дерматит ауруының бірінші ошақтарының өршуі

Ірі қара малдың кесек тері ауруы (КТА) — Африка континентінен шыққан ірі қара малдың трансшекаралық вирустық ауруы. Мұнда біз Қазақстан Республикасында 2016 жылдың шілдесінде тіркелген бірінші КТА індетін, сондай-ақ осы аурудың клиникалық көріністерін, диагностикалық әдістерді және қоздырғыштың одан әрі таралуымен күресу үшін қабылданған бақылау шараларын сипаттаймыз. Аурудың себебін анықтау үшін ауру және өлі жануарлардан, сонымен қатар жәндіктер мен кенелерден

үлгілер алынды. КТА ДНҚ-сы *Dermacentor marginatus* және *Hyalomma asiaticum* сынамаларының барлығында, *Tabanus bromius* сынамаларының 14,29%-да және *Stomoxys calcitrans* сынамаларының бірінде ПТР әдісімен анықталды. Эпидемиологиялық бірлік шегінде тіркелген 3557 бас ірі қара малдың ішінен 459 ірі қара мал ауру кезінде зардап шекті, оның ішінде ауырған мал 12,90 % және өлім-жітімі 0,96 % құрады. Бұл жұмыста эпидемиологиялық жағдай, диагноз, жаппай вакцинациялауды қоса алғанда, бақылау шаралары және ауру ошағын жою науқаны ұсынылған.

Кілт сөздер: бақылау шаралары, диагноз, эпидемиологиялық деректер, сүйелді дерматит, *Stomoxys calcitrans*, *Hematobia irritans*, ауру ошағы.

А.М. Исимов, Н.К. Кемалова, А.Т. Саржігітова, Б. Бахытжанқызы

Первая вспышка нодулярного дерматита крупного рогатого скота в Казахстане

Нодулярный дерматит (НД) — это новая трансграничная вирусная болезнь крупного рогатого скота, происходящая из африканского континента. Здесь мы описываем первую вспышку НД, зарегистрированную в Республике Казахстан в июле 2016 г., а также связанные с ней клинические проявления заболевания, методы диагностики и меры борьбы с дальнейшим распространением возбудителя. Для определения причины заболевания были взяты образцы от больных и мертвых животных, а также от насекомых и клещей. ДНК НД была обнаружена методом ПЦР во всех пробах от *Dermacentor marginatus* и *Hyalomma asiaticum*, в 14,29 % проб от *Tabanus bromius* и в одной из проб от *Stomoxys calcitrans*. Репродуктивный вирус НД был выделен из органов мертвого крупного рогатого скота и насекомых в культуре клеток LT и MDBK. Вирус накапливался в культурах клеток LT и MDBK на уровне третьего пассажа с титрами в диапазоне 5,5–5,75 log₁₀ TCID₅₀/см³. Во время вспышки количество пораженного крупного рогатого скота в пределах эпидемиологической единицы достигло 459 голов из 3557 зарегистрированных восприимчивых голов крупного рогатого скота с заболеваемостью 12,90 % и смертностью 0,96 %. В настоящей работе представлены эпидемиологическая ситуация, диагноз, меры борьбы, включая массовую вакцинацию и кампанию по искоренению очага болезни.

Ключевые слова: меры контроля, диагностика, эпидемиологические данные, нодулярный дерматит, *Stomoxys calcitrans*, *Hematobia irritans*, вспышка.